

3. Haffenden GP, Blenkinsopp WK, Ring NP, Wojnarowska F, Fry L. The potassium iodide patch test in dermatitis herpetiformis in relation to treatment with a gluten-free diet and dapsone. *Br J Dermatol* 1980;103:313-7.
4. Salo OP, Laiho K, Blomqvist K, Mustakallio KK. Papillary deposition of fibrin in iodide reactions in dermatitis herpetiformis. *Ann Clin Res* 1970;2:19-21.
5. Sciallis GF. Dermatitis herpetiformis and iodine. *Br J Dermatol* 1976;94:343.
6. Douglas WS, Alexander JOD. Dermatitis herpetiformis, iodine compounds, and thyrotoxicosis. *Br J Dermatol* 1975;92:596-8.
7. Landes E. Therapy resistance of a dermatitis herpetiformis Duhring to sulones, sulfonamides and steroids caused by iodoform dental filling [in German]. *Z Haut Geschlechtskr* 1960;28:306-7.

doi:10.1016/j.jaad.2008.08.041

The use of dermatoscopy to differentiate vestibular papillae, a normal variant of the female external genitalia, from condyloma acuminata

To the Editor: Vestibular papillae of the vulva are very small asymptomatic filiform or soft, frond-like projections on the vestibular epithelium or the inner aspect of the labia minora.^{1,2} This normal variant has a smooth surface and similar color to the adjacent mucosa.² Although common, the condition may be unfamiliar to clinicians and may be misdiagnosed as condyloma acuminata.³

A 39-year-old female presented with multiple papillary projections on the vulva. Three months earlier, she had complained of vulvodynia after childbirth and first recognized multiple grouped papillary projections on the inner left side of the labia minora. These had smooth surfaces and were the same color as the adjacent mucosa (Fig 1, A). At an obstetrics/gynecologic clinic, she was diagnosed as having condyloma acuminata, and at dermatologic clinic she was believed to have Bartholin adenitis. She was prescribed a first-generation cephalosporin (an oral dose of cephadrine 1 g a day for 7 days) for the presumed Bartholin adenitis. The vulvodynia improved, but the objective findings remained unchanged without associated itching or tenderness. Dermatoscopy with the DermLite II Pro (3Gen, San Juan, Capistrano, CA) demonstrated a regular, often symmetrical and linear, array of papillae over the vestibule. Individual vestibular papillae were juxtaposed, and their respective bases remained separate. Abundant, irregular vascular channels were observed in the transparent core of the papillae (Fig 1, B). Routine laboratory investigations and potassium hydroxide examinations were normal or negative. An excisional biopsy was performed; this showed anastomosing vascular projections covered by a normal epithelium with no histologic features of viral infection (Fig 2). Polymerase chain reaction

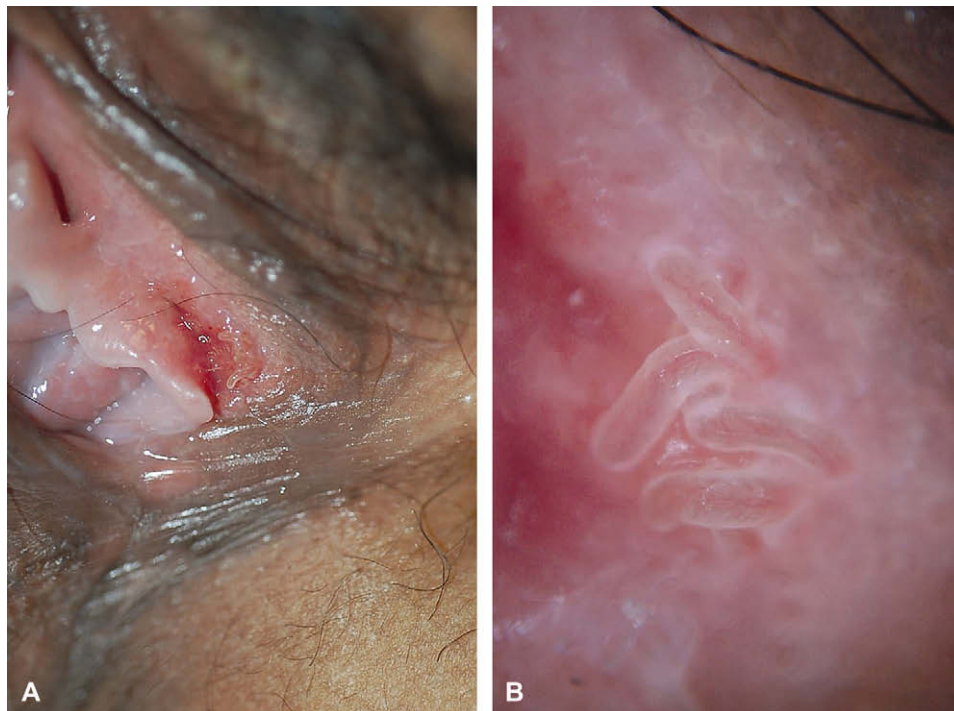


Fig 1. **A**, Multiple skin-colored, soft, frond-like projections on the left inner aspect of the labia minora. **B**, Dermatoscopic findings include multiple filiform projections with abundant vascular structures. The bases of the individual projections remain separate.

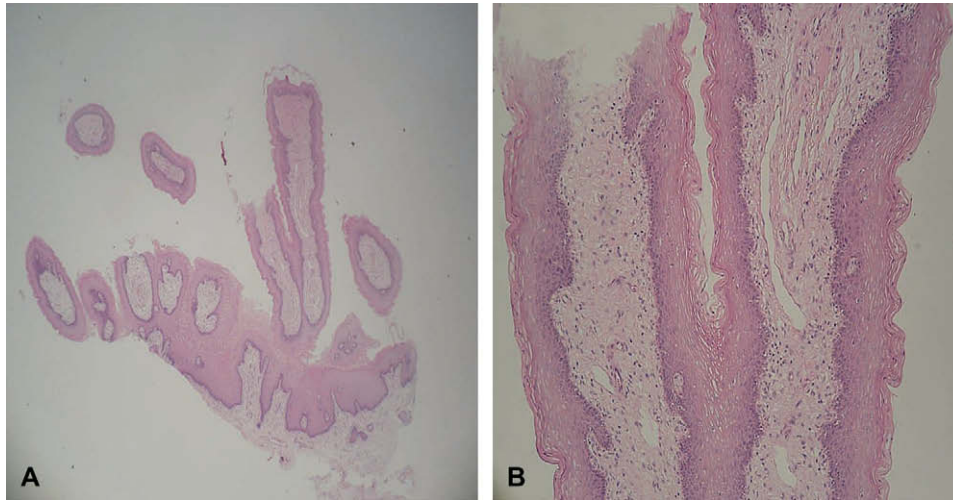


Fig 2. **A**, Prominent fibrovascular cores with chronic inflammation and dilated capillaries in the papillary projections. **B**, High power magnification. Koilocytes are not observed. (Hematoxylin–eosin stain; original magnification: **A**, $\times 20$; **B**, $\times 100$.)

Table I. Clinical differential diagnosis with vestibular papillae and condyloma acuminata

Clinical features	Vestibular papillae	Condyloma acuminata
Distribution	Symmetric or linear	Irregular
Palpation	Soft	Hard
Color	Pink, same as adjacent mucosa	Pink, white, and red lesions often associated
Base	Bases of individual projections remain separate	Superficial projections coalesce in a common base
Acetic acid test	No circumscribed whitening	Whitening in most cases

studies for human papillomavirus (HPV) were also negative.

Vestibular papillae were first described by Altmeyer.⁴ Synonyms have included papillomatosis labialis, hirsuties papillaris vulvae, hirsutoid papilloma of vulva, pseudocondylomas, vestibular microwarts, and vulvar squamous papillomatosis.^{2,4,5} Moyal-Barranco et al³ reported that vestibular papillae were not related to HPV infection. Using molecular hybridization, they detected HPV DNA sequences in only two (6.9%) of the 29 specimens of vestibular papillae, compared to 96% of specimens from vulvar warts. Vestibular papillae are now believed to represent an anatomic or functional variant of the normal genital epithelium. They are thought to be present in 1% of woman who visit obstetrics/gynecology clinics⁶ and are probably the female equivalent of pearly penile papules, the smooth, flesh-colored, and regularly distributed elevations of the corona of the glans penis.⁷ If a large number of papillae cover the entire surface of labia minora in a symmetric fashion, the condition is referred to as vestibular papillomatosis.⁸ Although vestibular papillae are usually asymptomatic, they

are often accompanied by itching, pain, burning, or dyspareunia.⁸ In our case, the patient visited the obstetrics/gynecologic clinic for vulvodynia in postpartum period. The lesions remained constant in size and shape after the pain disappeared. These normal anatomic structures could be misdiagnosed as condyloma acuminata, leading to inappropriate treatment.⁹ Moyal-Barranco et al³ suggested five clinical parameters that can be used to differentiate vestibular papillae from vulvar condylomata acuminata (Table I). In our case, we observed rod or teardrop shaped papillae. Individual papillae were juxtaposed, and their respective bases remained separate. We could confirm these finding using dermatoscopy. These clinical criteria differentiated vestibular papillae from condyloma acuminata without the need for HPV typing.

We are unaware of any previous report detailing the characteristic dermatoscopic findings of vestibular papillae versus condyloma acuminata. Dermatoscopy of vestibular papillae reveals abundant and irregular vascular channels in the transparent core of uniform-sized cylindrical papillae, which have separate bases. This differs from the



Fig 3. Dermoscopic findings of condyloma acuminata on vestibule of a 6-month-old girl show multiple irregular projections with tapering ends arising from a common base. The projections, whiter and broader than vestibular papillae, have conglomerate vascular structures.

dermoscopic appearance of condyloma acuminata. In our experience, dermoscopy of condyloma acuminata shows multiple, irregular projections with tapering ends arising from a common base. The projections have conglomerate vascular structures and are more white and broader than vestibular papillae; this might correlate with the hyperkeratotic and acanthotic features of condyloma acuminata (Fig 3). Therefore, along with the five clinical parameters suggested by Moyal-Barranco et al,³ we believe that characteristic dermoscopic findings provide additional diagnostic clues to differentiate vestibular papillae from condyloma acuminata.

Because vestibular papillae are unfamiliar to clinicians, they may be misdiagnosed as condyloma acuminata, leading to inappropriate treatment.⁹ Dermoscopy may represent a convenient and helpful modality in the diagnosis of vestibular papillae, especially when they resemble condyloma.

Su-Han Kim, MD,^a Sang-Hee Seo, MD,^a Hyun-Chang Ko, MD,^a Kyung-Sool Kwon, MD,^a and Moon-Bum Kim, MD^{a,b}

From the Department of Dermatology,^a School of Medicine, and the Medical Research Institute,^b Pusan National University, Busan, Korea

Funding sources: None.

Conflicts of interest: None declared.

Correspondence to: Moon-Bum Kim, MD, Department of Dermatology, School of Medicine, Pusan National University, 1-10 Ami-dong, Seo-gu, Busan, 602-739, Korea

E-mail: drkmp@hanmail.net

REFERENCES

1. Bunker CB, Neill SM. The genital, perianal and umbilical regions. In: Burns DA, Breathnach SM, Cox NH, Griffiths CEM, editors. Rook's textbook of dermatology, 7th ed, vol. 4. Oxford: Blackwell Publishing; 2004. pp. 53-68.
2. Woodruff JD, Friedrich EG Jr. The vestibule. Clin Obstet Gynecol 1985;28:134-41.
3. Moyal-Barracco M, Leibowitch M, Orth G. Vestibular papillae of the vulva. Lack of evidence for human papillomavirus etiology. Arch Dermatol 1990;126:1594-8.
4. Altmeyer P, Chliff GN, Holzman H. Pseudokondylome der vulva [in German]. Geburtshilfe Frauenheilkd 1981;41:783-6.
5. Friedrich EG Jr. The vulvar vestibule. J Reprod Med 1983;28:773-7.
6. Costa S, Rotola A, Terzano P, Secchiero P, Di Luca D, Poggi MG, et al. Is vestibular papillomatosis associated with human papillomavirus? J Med Virol 1991;35:7-13.
7. Ackerman AB, Kornberg R. Pearly penile papules. Arch Dermatol 1973;108:673-5.
8. Welch JM, Nayagam M, Parry G, Das R, Campbell M, Whatley J, et al. What is vestibular papillomatosis? A study of its prevalence, aetiology and natural history. Br J Obstet Gynaecol 1993;100:939-42.
9. Prieto MA, Gutierrez JV, Sambucety PS. Vestibular papillae of the vulva. Int J Dermatol 2004;43:143-4.

doi:10.1016/j.jaad.2008.08.031

Metastatic squamous cell carcinoma of the buttock treated with chemoradiation using cisplatin and 5-fluorouracil

To the Editor: We have previously reported two patients with locally advanced squamous cell carcinoma (SCC) of the skin who were successfully treated with chemoradiation using cisplatin (CDDP) and 5-fluorouracil (5-FU).¹ We proposed this therapy as an option in managing patients who have unresectable primary tumors or who require preservation of local function. In this report, we present a case of distant lymph node metastasis successfully treated with this chemoradiation protocol.

A 66-year-old male was seen in our institution in June 2004 with SCC of the buttock arising from a chronic bacterial pyoderma. He was treated by local excision and bilateral inguinal lymph node dissection, and the carcinoma was determined as being a stage III tumor (International Union Against Cancer staging, 2002). Serum SCC antigen levels decreased to near normal levels after surgery but increased again within 3 months (Fig 1). Computed